

DETERMINATION OF HUMAN VERSUS NON-HUMAN SKELETAL MATERIAL

Kathy Taylor, Ph.D.
Forensic Anthropologist
King County Medical Examiner's Office
Seattle, Washington, USA

The author of this document has authorized unrestricted copying and redistribution for educational/training purposes.

DETERMINATION OF HUMAN VERSUS NON-HUMAN BONES

The problem: All mammals have the same basic skeletal plan. Humans are just a variation on the theme.

The good news: Humans are the only bipedal mammal and so exhibit some fairly obvious morphological differences.

2 main areas of distinction:

- size
- morphology

SIZE:

-Immature skeletal materials exhibits epiphyses which make skeletal analysis of immature individuals a nightmare but does provide a valuable tool in the determination of human versus non-human. If you encounter a small long bone, for example, that looks like a complete human bone but is small (i.e. makes you think it might be from an infant or child) it is most likely NOT human. Human long bones are not complete (have the ends attached) until growth of the bone is complete.

-Size of the bone and areas of muscle attachment reflect muscle mass of the animal. This is most important for distinguishing adult long bones (bones of the extremities).

MORPHOLOGY:

-Humans are the only two-legged animals. Consequently, the bones of the trunk (particularly the pelvis and scapula) exhibit a unique morphology.

-There are differences in epiphyseal formation and morphology of smaller bones (i.e. metacarpals), which can prove useful.

A FEW TIPS....

Cranium: The most frequently recovered skeletal element and fortunately the most distinct. It can be tricky, however, when fragmentary. The best shot is to look at the teeth.

Adult dentition: 2 incisors, 1 canine, 2 premolars, 3 molars.

Subadult dentition: 2 incisors, 1 canine, 2 molars.

Non-human teeth often exhibit pointy cusps and large canines (on carnivores) or incisors (rodents).

Vertebrae: Non-human tend to have tall centra with small surface area for articulation and short, blocky spinous processes.



Human

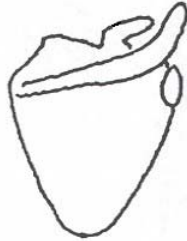

Non-human

**** Non-human vertebrae have an epiphyseal CAP. Humans have an epiphyseal RING.

Ribs: Non-human ribs tend to have small head, large tubercles. They tend to be flat, wide and have less curvature. Careful... ribs are tricky, especially when fragmentary.

Scapula: On many non-human animals, the widest dimension of the scapula is side to side (medial to lateral) with a large scapular spine.



Human

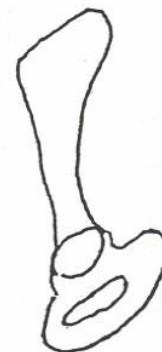

Non-human

Innominate: Refers to the 3 bones that make up each side of the pelvis. Humans have broad ilia (blade of pelvis creating bowel shape) and large acetabulums (for articulation with head of femur). Non-human animals have tall, thin ilia; are narrow anterior to posterior; and have small acetabulums.

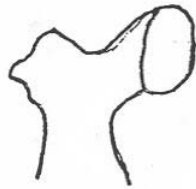


Human

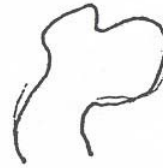

Non-human

Humerus/Femur: In non-human animals, the head may be incomplete (i.e. not completely round) and rarely is there a significant neck (bone between head and shaft).

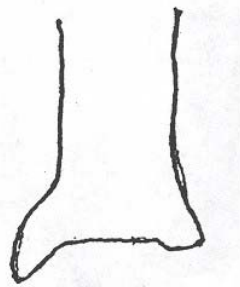


Human

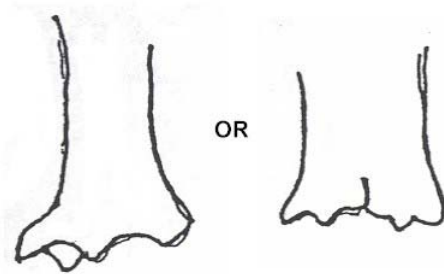


Non-human

Tibia: Non-human animals tend to have large tibial tuberosities, and a distal end with multiple extensions.



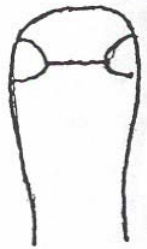Human



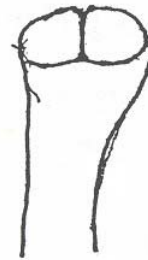Non-human

NOTE:

The non-human remains most commonly mistaken for human are bear paws which do look remarkably like human hands with one important (and extremely simple) difference. The head of a human metacarpal (bones of the hand) are smooth. On a bear, the head of the metacarpal has a ridge running down the middle.



Human



Non-human

If you are looking for good human osteology references, check out:

The Anatomy and Biology of the Human Skeleton. D. Gentry Steele and Claud A. Bramblett. Texas A&M University Press. 1988.

Human Osteology. Tim White. Academic Press. 1991.

Human Osteology: A Laboratory and Field Manual. William M. Bass. Missouri Archaeological Society, Inc. 1987.